

# Neuroblastoma of Posterior Mediastinum: Classical Imaging Findings

SWAPNDEEP SINGH ATWAL<sup>1</sup>**Keywords:** Neuroblastoma, CT imaging, Posterior mediastinum

## HISTORY

A 12-year old male patient presented in the paediatric clinic with occasional dull chest pain, dry cough and progressive weakness of the lower limbs since four months. His blood investigations were normal. Chest radiograph posteroanterior view demonstrated a soft tissue mass in the left hemithorax which was further characterized by lateral chest radiograph [Table/Fig-1] and contrast enhanced computed tomography (CT) [Table/Fig-2]. The patient underwent surgery to remove the mass and its intraspinal component which was causing cord compression. The patient recovered with marked relief in his symptoms. He was on chemotherapy.

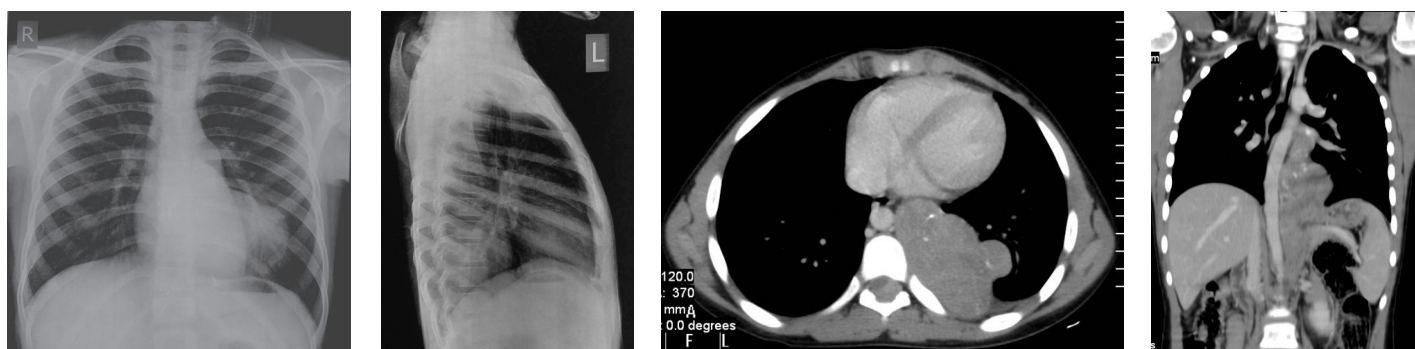
## DISCUSSION

In the present case, chest radiograph posteroanterior view revealed a well defined homogenous soft tissue density in the retro cardiac and left cardio-phrenic region which is broad based towards mediastinum and forming obtuse angle with it. No calcification areas were seen within the lesion. Lesion is overlapping but not silhouetting the left cardiac border suggesting that the mass is not located in the middle mediastinum [Table/Fig-1]. In order to further compartmentalize the lesion, lateral chest radiograph was done which revealed that the mass is overlapping lower thoracic vertebrae suggesting posterior mediastinal location of the mass [Table/Fig-2]. On the basis of chest radiographs findings the possible differentials were tumours arising from sympathetic ganglia like neuroblastoma, ganglioneuroma, ganglioneuroblastoma and peripheral nerve sheath tumours like neurofibroma and schwannoma. Contrast enhanced

computed tomography (CT) chest was subsequently done to further characterize the lesion and to delineate the complete extension of the mass lesion. CT showed a well defined lobulated enhancing soft tissue density mass in left paravertebral region with intraspinal extension through the neural foramina. It was compressing and displacing the thoracic spinal cord towards right. Few punctate calcific foci were also seen within the mass [Table/Fig-3]. The mass appeared elongated along left paravertebral location from ninth thoracic to second lumbar vertebra. It was abutting and displacing the descending aorta but not invading it [Table/Fig-4]. The lesion was posterior mediastinal neuroblastoma confirmed histopathologically. Neurogenic tumours are the most common posterior mediastinal masses accounting approximately 90 percent of the cases [1]. Neuroblastoma is the most common neurogenic tumour in paediatric age group. Mean age of presentation is below 2 years. In our case, it presented at slightly higher age. The mass can extend into spinal canal through neural foramen and can compress the cord leading to various neurological symptoms as in our case [2]. Calcification can be seen in about 30% and 80% of cases on plain radiographs and CT respectively [3]. Treatment includes surgical removal of mass and chemotherapy.

## REFERENCES

- [1] Fraser RS, Muller NL, Colman NC, Pare PD. Fraser and Pare's Diagnosis of diseases of the chest. 4<sup>th</sup>Edn. Philadelphia: W. B. Saunders; 1999.
- [2] Matthy KK. Neuroblastoma: a clinical challenge and biologic puzzle. *CA Cancer J Clin.* 1995. 45(3): 179-92.
- [3] Stark DD, Moss AA, Brasch RC, et al. Neuroblastoma: diagnostic imaging and staging. *Radiology.* 1983; 148:101-05.



**[Table/Fig-1]:** Chest radiograph postero-anterior view: well defined homogenous soft tissue opacity in retro cardiac and left cardiophrenic region which is broad based towards mediastinum and forming obtuse angle with it. No calcification areas seen within the lesion. Lesion is overlapping but not silhouetting the left cardiac border

**[Table/Fig-2]:** Chest radiograph lateral view: mass is overlapping lower thoracic vertebrae suggesting posterior mediastinal location of the mass

**[Table/Fig-3]:** Contrast enhanced CT chest axial image in mediastinal window settings: Well defined lobulated enhancing soft tissue density mass in left paravertebral region with intraspinal extension. Mass is compressing and displacing the spinal cord towards right. Few punctate calcific foci are seen within the mass

**[Table/Fig-4]:** Contrast enhanced CT chest Coronal image in mediastinal window settings: The mass is elongated along left paravertebral location from ninth thoracic to second lumbar vertebra. Mass is abutting and displacing the descending aorta but not invading it

### PARTICULARS OF CONTRIBUTORS:

1. Senior Resident, Department of Radiology, Dr. Ram Manohar Lohia Hospital and PGIMER, New Delhi, India.

### NAME, ADDRESS, E-MAIL ID OF THE CORRESPONDING AUTHOR:

Dr. Swapndeep Singh Atwal,  
8/4, 3<sup>rd</sup> Floor, old Rajender Nagar, New Delhi-110060, India.  
Phone : 9013837423, E-mail : swapndeepsinghatwal@gmail.com

**FINANCIAL OR OTHER COMPETING INTERESTS:** None.

Date of Submission: **Jan 31, 2014**

Date of Peer Review: **Jun 13, 2014**

Date of Acceptance: **Jul 02, 2014**

Date of Publishing: **Oct 20, 2014**